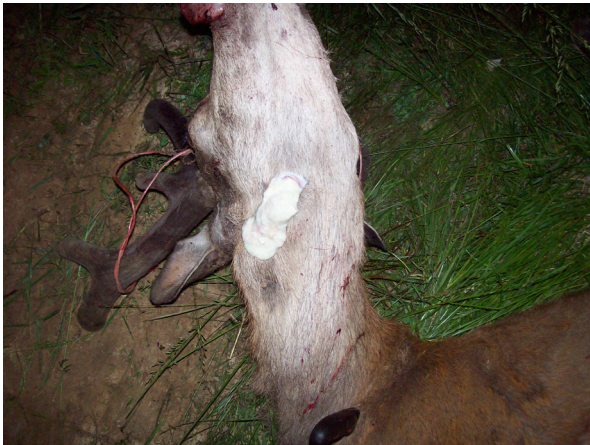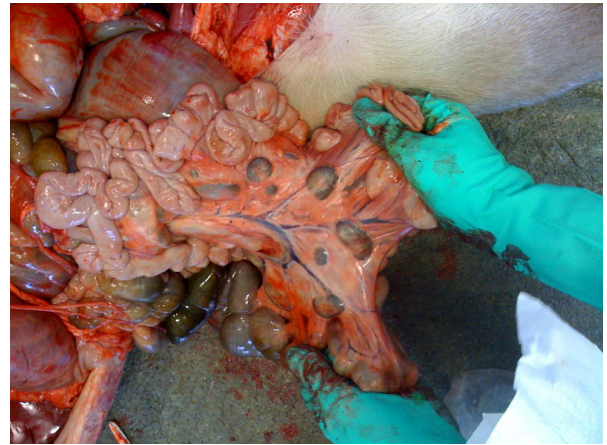


# Bovine Tuberculosis Abscesses and Lesions



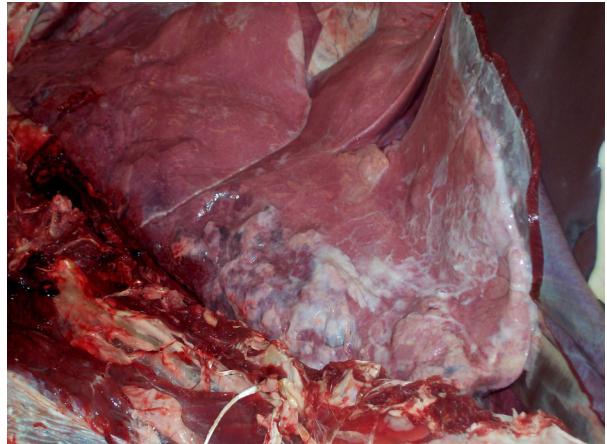Abscessed lymph nodes in the neck. When ruptured, material is thick, yellowish or greenish without odor



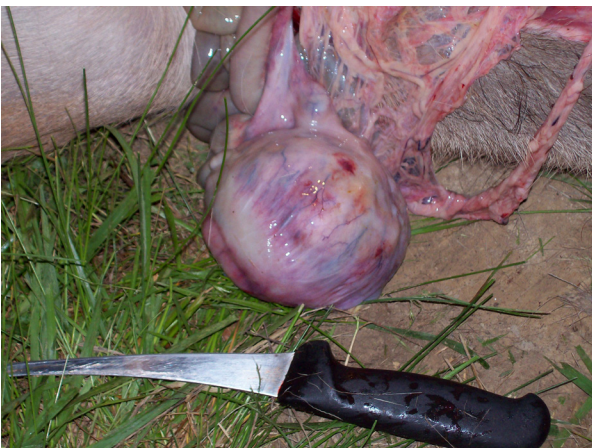
Abnormal lymph nodes; large and dark in color



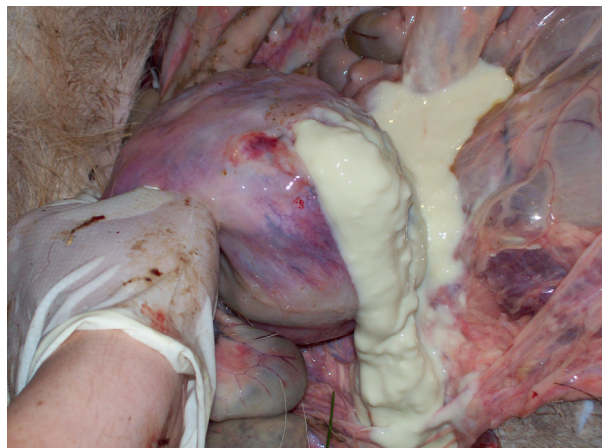
Pearl abscesses on inside lining of rib cage, may be as small as the tip of a finger



Lung lobes with chronic pneumonia and abscesses



Large abscess within abdominal cavity may be large (grapefruit-sized) or very small



If you see any lesions,  
consult a veterinarian by calling (toll-free) at:  
**877/747-3038 ext. 2402**  
More information available at: [www.boah.in.gov](http://www.boah.in.gov)

